

## Case Report

# Sonological Appearance of Epidermoid Cyst of the Spleen: A Rarity

Reddy Ravikanth\*

Department of Radiology, St. John's Hospital, Kattappana, Kerala, India

## Abstract

Epidermoid cyst of the spleen is a rare, benign cystic lesion of congenital origin. Although most epidermoid cysts of the spleen are asymptomatic and detected incidentally on ultrasonography, the entity needs to be included in the differential diagnosis of cystic lesion mimics of the spleen, especially in patients with left hypochondriac pain. This case report describes the typical sonological appearance of epidermoid cyst of the spleen in a 31-year-old male.

**Keywords:** Epidermoid cyst, spleen, ultrasonography

## INTRODUCTION

Splenic cysts are rare lesions which may be congenital, neoplastic, vascular, inflammatory, and posttraumatic in origin. Epidermoid cyst of the spleen is a true cyst which is congenital in origin and commonly encountered in children and young adults. A definitive diagnosis of the lesion is made based on the findings on splenectomy when the epithelial lining of the cyst is confirmed histologically.

## CASE REPORT

A 31-year-old gentleman presented to the surgery department with complaints of insidious onset dull aching pain in the left hypochondrium for 3 months. There were no complaints of fever or association with food intake and no specific relieving factor. Transabdominal ultrasonography revealed moderate splenomegaly with evidence of a well-defined cystic lesion measuring 8 cm × 6 cm × 8 cm with coarse diffuse internal echoes and no solid component located in the upper pole of the spleen at the left subdiaphragmatic location [Figure 1a and b]. A diagnosis of the splenic epidermoid cyst was made on ultrasonography. Preoperative computed tomography (CT) findings confirmed the splenic origin of the cyst [Figure 2]. The patient was referred to the department of general surgery for splenectomy and further management. Histopathological

examination revealed findings suggestive of a primary (true) cyst.

## DISCUSSION

Epidermoid cyst of the spleen is a congenital cyst and the rarest entity among all the true cysts that occur in the spleen. Approximately 20% of all cysts that occur in the spleen are true cysts which possess an epithelial lining.<sup>[1]</sup> Etiology is related to the embryogenesis phase of intrauterine life when peritoneal mesothelial cells get entrapped within the splenic parenchyma. Epidermoid cyst of the spleen is benign and a noninfective lesion. On ultrasonography, the lesion appears as a well defined, thin walled cyst with diffuse internal echoes and occasionally may demonstrate internal septations, debris and trabeculations. Occasionally, epidermoid cysts may demonstrate a peripheral rim of calcification which may be plaque like or curvilinear as described in the index case. On CT images, epidermoid cysts are round, well-demarcated nonenhancing lesions with near water attenuation.<sup>[2]</sup> In contrast, false cysts which demonstrate no cellular lining have varied appearances on ultrasonography such as peripheral egg-shell calcifications and thick fibrous wall.<sup>[3]</sup> False cysts should be

**Address for correspondence:** Dr. Reddy Ravikanth,  
Department of Radiology, St. John's Hospital,  
Kattappana - 685 515, Kerala, India.  
E-mail: [ravikanthreddy06@gmail.com](mailto:ravikanthreddy06@gmail.com).

Received: 28-10-2020 Revised: 20-01-2021 Accepted: 02-03-2021 Available Online: 06-07-2021

### Access this article online

#### Quick Response Code:



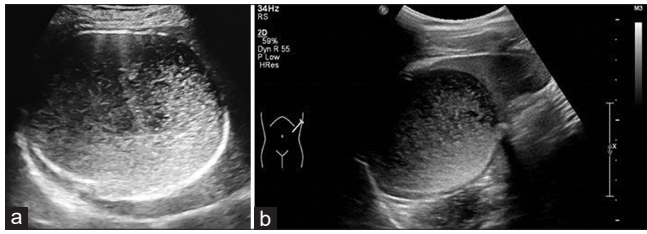
**Website:**  
[www.jmuonline.org](http://www.jmuonline.org)

**DOI:**  
10.4103/JMU.JMU\_153\_20

This is an open access journal, and articles are distributed under the terms of the Creative Commons Attribution-NonCommercial-ShareAlike 4.0 License, which allows others to remix, tweak, and build upon the work non-commercially, as long as appropriate credit is given and the new creations are licensed under the identical terms.

**For reprints contact:** [WKHLRPMedknow\\_reprints@wolterskluwer.com](mailto:WKHLRPMedknow_reprints@wolterskluwer.com)

**How to cite this article:** Ravikanth R. Sonological appearance of epidermoid cyst of the spleen: A rarity. J Med Ultrasound 2022;30:153-4.



**Figure 1:** (a) Transabdominal ultrasonography image demonstrating a well-defined cystic lesion at the superior pole of the spleen with coarse diffuse internal echoes. The sonological appearance is typical of epidermoid cyst of the spleen. (b) Transabdominal ultrasonography image demonstrating debris-containing cystic mass without solid component. Note: the “claw” sign suggesting the splenic origin of the cystic lesion

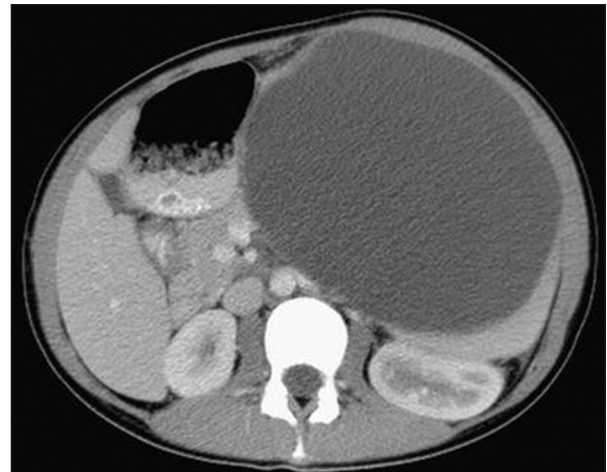
avored with a history of trauma. These imaging features help to differentiate true cysts from false cysts. Differential diagnoses for cystic lesions in the spleen are splenic hydatid cyst, splenic epidermoid cyst of congenital origin, splenic abscess, pancreatic pseudocyst, cystic neoplasm-like splenic lymphangioma, and cystic metastases. Epidermoid cyst of the spleen may present with complications such as infection, hemorrhage into the cyst, or rupture.

## CONCLUSION

This case report describes the sonological appearance of a splenic epidermoid cyst which is a rare entity and should be included in the differential diagnosis of cystic lesions of the spleen. Radiologists and sonologists must be aware of the sonological appearance to confidently diagnose the lesion with precision and to avoid unnecessary biopsy and further imaging.

## Declaration of patient consent

The authors certify that they have obtained all appropriate patient consent forms. In the form, the patient has given his



**Figure 2:** Axial contrast-enhanced computed tomography image demonstrating a well-defined cystic lesion of splenic origin with no enhancement or solid component

consent for his images and other clinical information to be reported in the journal. The patient understands that his name and initials will not be published and due efforts will be made to conceal the identity, but anonymity cannot be guaranteed.

## Financial support and sponsorship

Nil.

## Conflicts of interest

There are no conflicts of interest.

## REFERENCES

1. Ingle SB, Hinge Ingle CR, Patrike S. Epithelial cysts of the spleen: A minireview. *World J Gastroenterol* 2014;20:13899-903.
2. Marjanović ZO, Djordjević IM. Epidermoid splenic cysts in children and adolescents. *Acta Chir Jugosl* 2008;55:63-7.
3. Kalinova K. Giant pseudocyst of the spleen: A case report and review of the literature. *J Indian Assoc Pediatr Surg* 2005;10:176-78.